

Alveolar Soft-Part Sarcoma Responsive to Intensive Chemotherapy

H. James Nickerson, MD,* Teresa Silberman, MD,* F. Stig Jacobsen, MD,† Bruce R. Krawisz, MD,‡ Hope S. Maki, MD,§ and Carola A. S. Arndt, MD||

Abstract: Alveolar soft-part sarcoma (ASPS) is a very rare malignant tumor, usually of the extremities, and is seen most often in adolescents and young adults. Surgical excision of the primary and pulmonary metastases has resulted in prolonged survival in some patients, but adjuvant radiation and/or chemotherapy are generally thought to be ineffective. The authors describe a 13-year-old patient with ASPS of an extremity who presented with multiple bilateral pulmonary metastases at diagnosis. Following intensive multiagent chemotherapy, pulmonary metastases showed in vivo evidence of tumor death. The patient has remained disease-free for 10 years following treatment.

Key Words: alveolar soft-part sarcoma, pulmonary metastases, chemotherapy, ifosfamide, etoposide

(*J Pediatr Hematol Oncol* 2004;26:233–235)

Alveolar soft-part sarcoma (ASPS) was first described as a separate entity in 1952.¹ Prior to that time, it had been described by many different names: synovioma, angioreninoma, rhabdomyoma, hemangioma, liposarcoma, rhabdomyosarcoma, granular myoblastoma, and malignant tumor of non-chromaffin paraganglia.²

ASPS represents less than 1% of all sarcomas in children and adults.^{3–5} The average age at diagnosis is 20 years for women and 30 years for men. The tumor is frequently localized in the lower extremities in adults⁶ and in the head and neck (especially the orbit and tongue) in children.^{1–4,7,8} Debate and controversy exist regarding the derivation of ASPS.² Metastases commonly appear in the lung and brain.⁶

ASPS is a slow-growing, indolent tumor with metastases that may appear late.⁶ Even though its progression is indolent,

it is considered to be a malignant tumor. All ASPS tumors are considered high grade, and in the long run ASPS is usually a fatal disease. Death has occurred from disseminated sarcoma as late as 20 years after diagnosis. After surgical excision of the primary tumor, local recurrence occurs in 11% to 50% of patients.⁹ The survival rate is reported to be 45% to 88% at 5 years, 38% at 10 years, and 15% at 20 years.^{6,9,10} Children have better overall survival compared with adults.¹¹

Surgical excision with an attempt at obtaining tumor-free margins is accepted as the treatment of choice for both primary tumors and metastatic tumors in the brain and lung.^{12,13} It is commonly believed that adjuvant radiation therapy and/or chemotherapy do not provide any improvement in disease control or survival.¹² We describe an adolescent patient in whom a large proportion of pulmonary ASPS metastases responded to aggressive multiagent chemotherapy, including ifosfamide and etoposide. The Institutional Review Board office of Marshfield Clinic Research Foundation has determined that reporting of this case does not require Institutional Review Board approval.

CASE REPORT

A 13-year-old patient presented with a 2-month history of increasing left leg pain with a palpable mass in the left popliteal region. An initial biopsy confirmed ASPS with nests of large, loosely arranged polygonal cells surrounded by capillaries, resembling alveoli.¹ Cells exhibited characteristic periodic acid Schiff–positive, diastase-resistant crystalline materials intracellularly (Fig. 1).^{3,7} The initial biopsy had gross margins that were disease-free, but this was not considered adequate for sarcoma surgery. The initial CT scan of the chest done before the limb salvage procedure showed bilateral pulmonary nodules. There were two on the left, measuring 4 to 8 mm, and two on the right, measuring 4 mm in largest diameter. A radical re-excision limb salvage procedure was then performed, taking down the whole head of the lateral gastrocnemius and the soleus muscles. The flexor hallucis longus was also excised. All margins were free of disease.

Following informed consent, the patient was started on the soft tissue sarcoma chemotherapy protocol of the Clinical Oncology Group of the Upper Midwest (COGUM-91-91-10).

Received for publication September 2003; accepted January 2004.

From the *Department of Pediatrics, Marshfield Clinic, Marshfield, Wisconsin; †Department of Orthopaedics, Marshfield Clinic, Marshfield, Wisconsin; ‡Department of Pathology, Marshfield Clinic, §Department of Cardiovascular Surgery, Marshfield Clinic, Marshfield, Wisconsin; and ||Department of Pediatric and Adolescent Medicine, Mayo Clinic, Rochester, Minnesota.

Reprints: H. James Nickerson, MD, Department of Pediatrics, Marshfield Clinic, 1000 North Oak Avenue, Marshfield, WI 54449 (e-mail: nickerson.harlan@marshfieldclinic.org).

Copyright © 2004 by Lippincott Williams & Wilkins

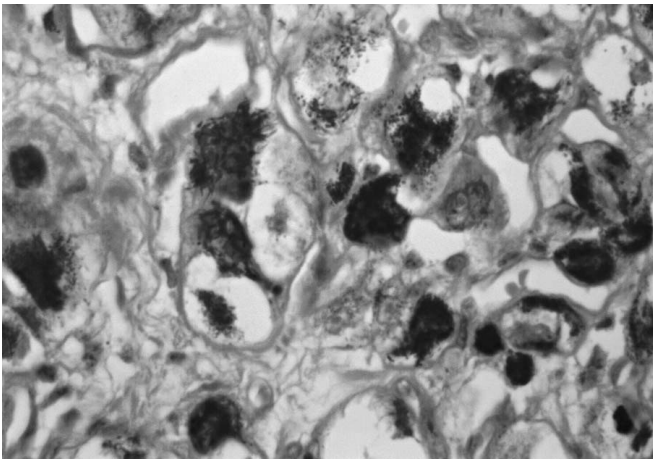


FIGURE 1. Photomicrograph ($\times 400$, PAS with diastase) of patient's primary tumor of the posterior left leg. The neoplasm shows the characteristic features of alveolar soft part sarcoma, including PAS-positive cytoplasmic rod-shaped crystals, abundant cytoplasm, sharply defined cell borders, and vesicular nuclei with prominent nucleoli.

This therapy consisted of cyclic courses of vincristine (2 mg/m^2 intravenously), cyclophosphamide ($1,200 \text{ mg/m}^2$ with 360 mg/m^2 of mesna [2-mercaptoethane sulfonate] intravenously), and doxorubicin (75 mg/m^2 as a continuous 48 hour infusion for 2 days), alternated every 3 weeks with 5 days of etoposide (100 mg/m^2 intravenously over 1 hour) followed by ifosfamide ($1,800 \text{ mg/m}^2$ with 360 mg/m^2 of mesna intravenously over 1 hour) for six cycles. The total chemotherapy lasted 36 weeks.

After the first two cycles of therapy (12 weeks), a left thoracotomy was performed and 13 metastatic nodules were removed. They measured 2 to 4 mm in largest diameter. Four of the 13 nodules were positive for ASPS. The metastatic tumors were discretely nodular and eosinophilic without alveolar pattern (Fig. 2). The remaining 16 fibrotic nodules showed necrosis and evidence of cell death, typical of tumors responding to chemotherapy.

Six weeks later a total of 11 nodules were removed from the right lung, with the largest diameter being 4 mm. Four of the 11 nodules were positive for tumor. Altogether, in both lungs 16 of 24 pulmonary nodules showed *in vivo* tumor cell destruction. The patient remains disease-free and clinically well with full activity over 10 years since the initial diagnosis.

DISCUSSION

While surgical resection of ASPS primary and metastatic tumors remains the treatment of choice, the identification of an effective adjuvant chemotherapy to kill residual and micrometastatic tumors, especially for children, remains a challenge.¹¹ It is difficult to obtain adequate margins and prevent hematogenous spread during surgical resection, and both

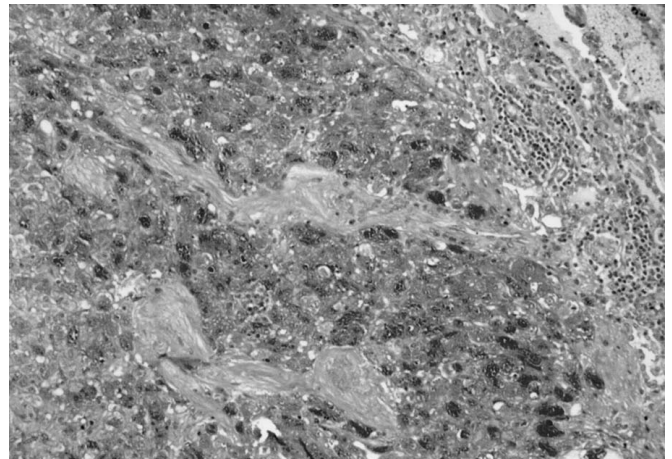


FIGURE 2. Photomicrograph ($\times 100$, PAS with diastase) of a pulmonary metastasis resected 7 months after diagnosis of the primary tumor. This pulmonary metastasis is similar to the primary tumor but contains areas of fibrosis.

local recurrence and distant metastases may result.¹² Adjuvant radiation therapy has been given to some children, but the effects are difficult to evaluate.¹¹

The intensity of the chemotherapy used in our patient seems to have been effective on the smaller pulmonary metastatic tumors, where only fibrous tissue remained. The size of the primary tumor may correlate with survival: worse survival rates ensue when the tumor diameter is more than 5 cm. Others, however, could not demonstrate any correlation between survival and clinical presentation, histology grade, vascular invasion, or p53 mutation.¹⁴ In our patient, the complete *in vivo* killing of 67% (16/24) of pulmonary ASPS metastases suggests significant sensitivity to a five-drug chemotherapy regimen containing ifosfamide and etoposide.

Chemotherapy has been used in several reported adolescents with ASPS, but only one of eight has been a long-term survivor greater than 46 months.^{11,15,16} Six patients have received ifosfamide ($n = 6$) and/or etoposide ($n = 4$).^{11,16} Most nonembryonal soft tissue sarcomas respond poorly to chemotherapy.¹⁷ Regimens containing doxorubicin, cyclophosphamide, cisplatin, vincristine, dacarbazine, and other agents have not been shown to be effective in the preoperative and/or postoperative treatment of ASPS.^{11,18}

While adjuvant chemotherapy is generally believed to be of little value, other reports now question this assumption. Baum et al reported a case in which 92 malignant pulmonary ASPS metastases were surgically excised, followed by adjuvant combination chemotherapy (vincristine, actinomycin D, cyclophosphamide, and doxorubicin), resulting in disease-free survival for at least 5 years.¹⁹ Although radiotherapy and chemotherapy have occasionally been reported to produce regression or slow the spread of metastases,^{18,20} no results of controlled studies are available.

Both ifosfamide and doxorubicin have been shown to be active against adult soft tissue sarcomas.²¹ In children, ifosfamide alone has been found to be active in a range of sarcomas resistant to cyclophosphamide treatment.²² Objective partial response to etoposide alone has similarly been reported in children with rhabdomyosarcoma and Ewing sarcoma.²³ In recurrent soft tissue sarcomas treated with only ifosfamide and etoposide in similar doses as our patient, 56% of 77 children and young adults had either a partial or complete response to this therapy alone.¹⁷ None of these patients had ASPS, however. In another study, adding eight cycles of ifosfamide and etoposide to standard intermediate-risk rhabdomyosarcoma and undifferentiated rhabdomyosarcoma resulted in an overall survival of 91% at 3 years.²⁴

Because of the indolent nature of ASPS and the prolonged interval between primary presentation and the appearance of metastases, the 10-year disease-free survival of our patient is encouraging. However, the large proportion of pulmonary metastases responding in vivo to an aggressive five-drug chemotherapy regimen incorporating ifosfamide and etoposide suggests that this chemotherapeutic regimen may have a role in the adjuvant therapy for surgically treated ASPS.

ACKNOWLEDGMENTS

The authors thank Marshfield Clinic Research Foundation for its support through the assistance of Alice Stargardt and Graig Eldred in the preparation of this manuscript.

REFERENCES

1. Christopherson VM, Foote FM, Stewart FW. Alveolar soft part sarcoma: structurally characteristic tumors of uncertain histogenesis. *Cancer*. 1952; 5:100-111.
2. Hunter BC, Devaney KO, Ferlito A, et al. Alveolar soft part sarcoma of the head and neck region. *Ann Otol Rhinol Laryngol*. 1998;107:810-814.
3. Castle JT, Goode RK. Alveolar soft part sarcoma of the tongue: a report of an unusual pattern in a child. *Ann Diagn Pathol*. 1999;3:315-317.
4. Ordonez NG. Alveolar soft part sarcoma: a review and update. *Adv Anat Pathol*. 1999;6:125-139.
5. Rao BN. Nonrhabdomyosarcoma in children: prognostic factors influencing survival. *Semin Surg Oncol*. 1993;9:524-531.
6. Auerbach HE, Brooks JJ. Alveolar soft part sarcoma. A clinicopathologic and immunohistochemical study. *Cancer*. 1987;60:66-73.
7. Batsakis JG. Alveolar soft-part sarcoma. *Ann Otol Rhinol Laryngol*. 1988; 97:328-29.
8. Jordan DR, MacDonald H, Noel L, et al. Alveolar soft-part sarcoma of the orbit. *Ophthalmic Surg*. 1995;26:269-270.
9. Portera CA Jr, Ho V, Patel SR, et al. Alveolar soft part sarcoma: clinical course and patterns of metastasis in 70 patients treated at a single institution. *Cancer*. 2001;91:585-591.
10. Nakashima Y, Kotoura Y, Kasakura K, et al. Alveolar soft-part sarcoma. A report of ten cases. *Clin Orthop*. 1993;(294):259-266.
11. Pappo AS, Parham DM, Cain A, et al. Alveolar soft part sarcoma in children and adolescents: clinical features and outcome of 11 patients. *Med Pediatr Oncol*. 1996;26:81-84.
12. Kodama K, Doi O, Higashiyama M, et al. Surgery for multiple lung metastases from alveolar soft-part sarcoma. *Surg Today*. 1997;27:806-811.
13. Simmons WB, Haggerty HS, Ngan B, et al. Alveolar soft part sarcoma of the head and neck. A disease of children and young adults. *Int J Pediatr Otorhinolaryngol*. 1989;17:139-153.
14. Jong R, Kandel R, Fornasier V, et al. Alveolar soft part sarcoma: review of nine cases including two cases with unusual histology. *Histopathology*. 1998;32:63-68.
15. Berenzweig MS, Muggia FM, Kaplan BH. Chemotherapy of alveolar soft-part sarcoma: a case report. *Cancer Treat Rep*. 1977;61:77-79.
16. Kuriyama K, Todo S, Hibi S, et al. Alveolar soft part sarcoma with lung metastases. Response to interferon alpha-2a? *Med Pediatr Oncol*. 2001; 37:482-483.
17. Miser JS, Kinsella TJ, Triche TJ, et al. Ifosfamide with mesna uroprotection and etoposide: an effective regimen in the treatment of recurrent sarcomas and other tumors of children and young adults. *J Clin Oncol*. 1987; 5:1191-1198.
18. Raney RB Jr. Proceedings of the Tumor Board of the Children's Hospital of Philadelphia: alveolar soft-part sarcoma. *Med Pediatr Oncol*. 1979;6: 367-370.
19. Baum E, Fickenscher L, Nachman JB, et al. Pulmonary resection and chemotherapy for metastatic alveolar soft-part sarcoma. *Cancer*. 1981;47: 1946-1948.
20. Berman TM, Fuhrman SA, Johnson FE. Prolonged survival after bilateral thoracotomy for metastatic alveolar soft-part sarcoma. *Minn Med*. 1984; 67:261-262.
21. Loehrer PJ Sr, Sledge GW Jr, Nicaise C, et al. Ifosfamide plus doxorubicin in metastatic adult sarcomas: a multi-institutional phase II trial. *J Clin Oncol*. 1989;7:1655-1659.
22. Magrath I, Sandlund J, Raynor A, et al. A phase II study of ifosfamide in the treatment of recurrent sarcomas in young people. *Cancer Chemother Pharmacol*. 1986;18(Suppl 2):S25-28.
23. Chard RL Jr, Krivit W, Bleyer WA, et al. Phase II study of VP-16-213 in childhood malignant disease: a Children's Cancer Study Group Report. *Cancer Treat Rep*. 1979;63:1755-1759.
24. Arndt CA, Nascimento AG, Schroeder G, et al. Treatment of intermediate risk rhabdomyosarcoma and undifferentiated sarcoma with alternating cycles of vincristine/doxorubicin/cyclophosphamide and etoposide/ifosfamide. *Eur J Cancer*. 1998;34:1224-1229.